



Blood
Disorders
Day 2018

FOR

Health Professionals

Solving Medical Mysteries

Deducing diagnoses from clues in the CBC

Donald S. Houston MD PhD FRCPC



UNIVERSITY
OF MANITOBA



CancerCare Manitoba
COMMUNITY ONCOLOGY PROGRAM

Presenter Disclosure

- **Faculty / Speaker's name: Donald S. Houston**
- **Relationships with commercial interests:**
 - **None**
- **Relationship to Sherlock Holmes - aspirational**

Learning Objectives

1. Decipher the meaning of cryptic red cell indices in cases of anemia
2. Interrogate pale suspects with the use of the reticulocyte count
3. Inspect the white cell differential and the blood film to collar the perpetrators of hematological disease

Case 1: The Red Herring

- 67F presented to ER with atypical chest pain
- CBC showed:
 - WBC 4.1, Hb 134, MCV 77, RDW 14.5%, platelets 260
 - Neut 33.5%, Lym 59.1%, Mono 6.4%, Eos 0.8%, Baso 0.2%
- Routine chemistries (creatinine, LFTs, bili, LDH) all normal; mild persisting troponinemia

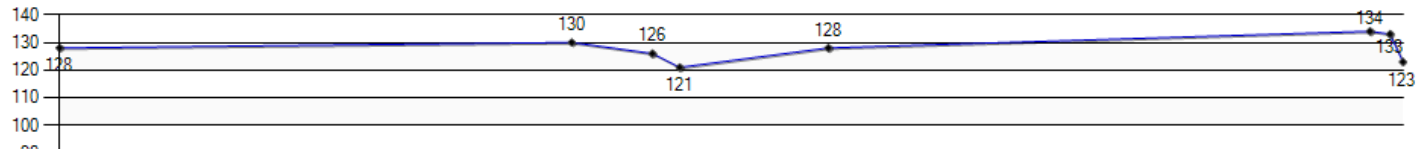
Case 1: What clues to pursue next?

What about the low MCV? How should we investigate?

- A. Serum iron and TIBC
- B. Serum ferritin
- C. ESR
- D. Hemoglobin electrophoresis
- E. Review old CBCs

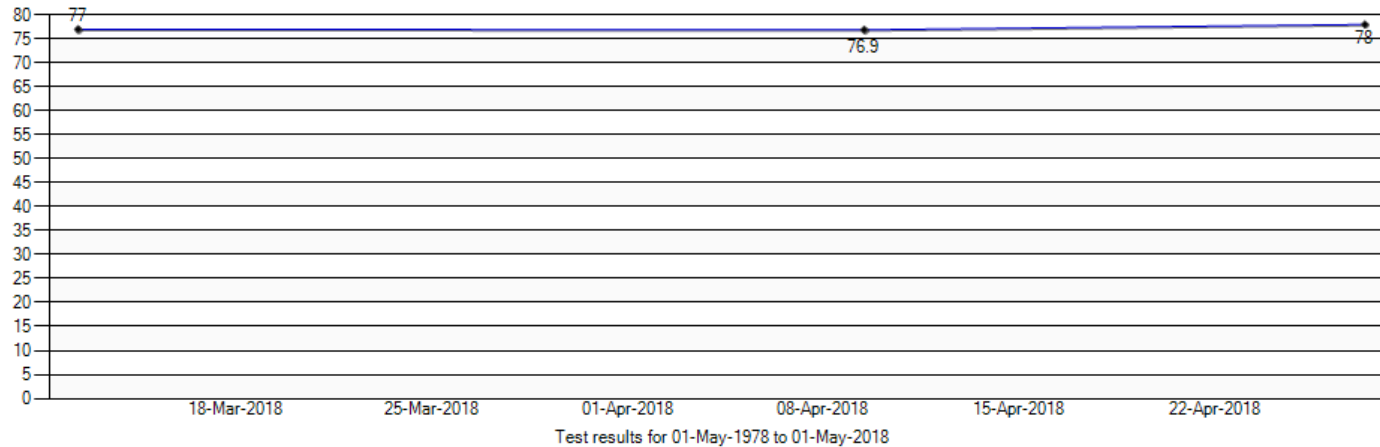
Hemoglobin

Warning: Notice that the results have undefined/different units of measure.

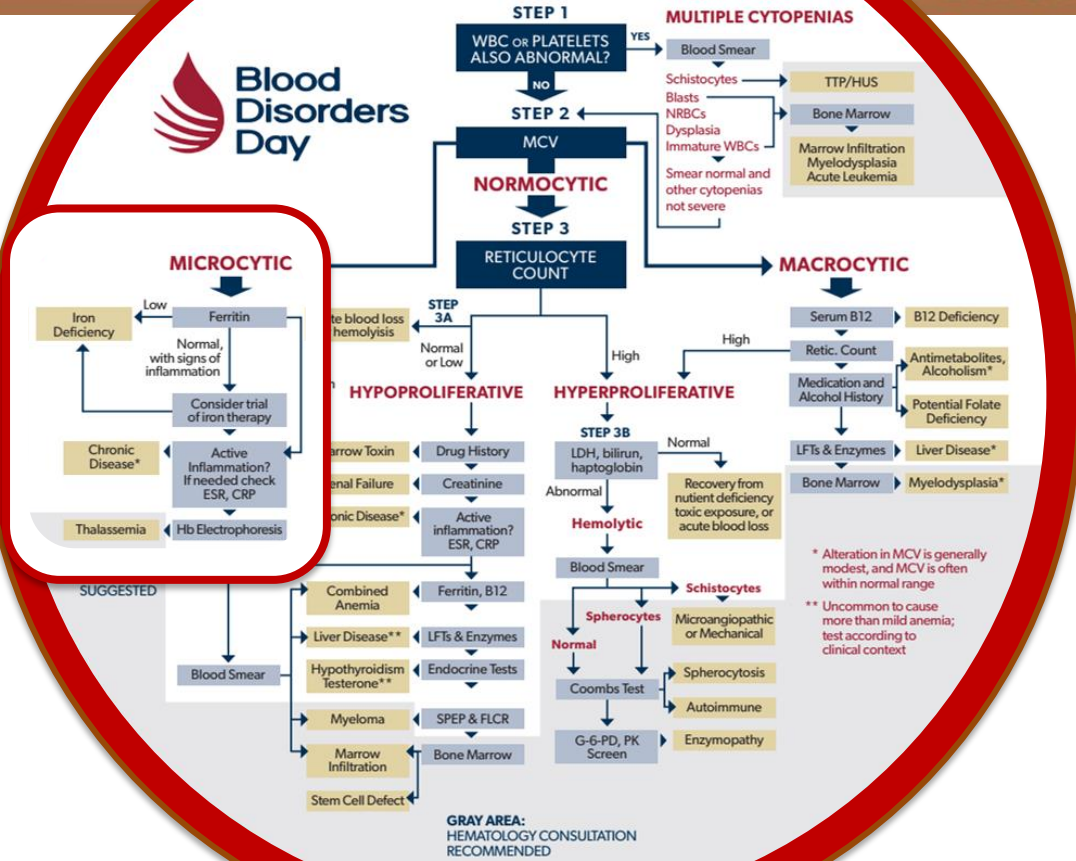


MCV

Warning: Notice that the results have undefined/different units of measure.

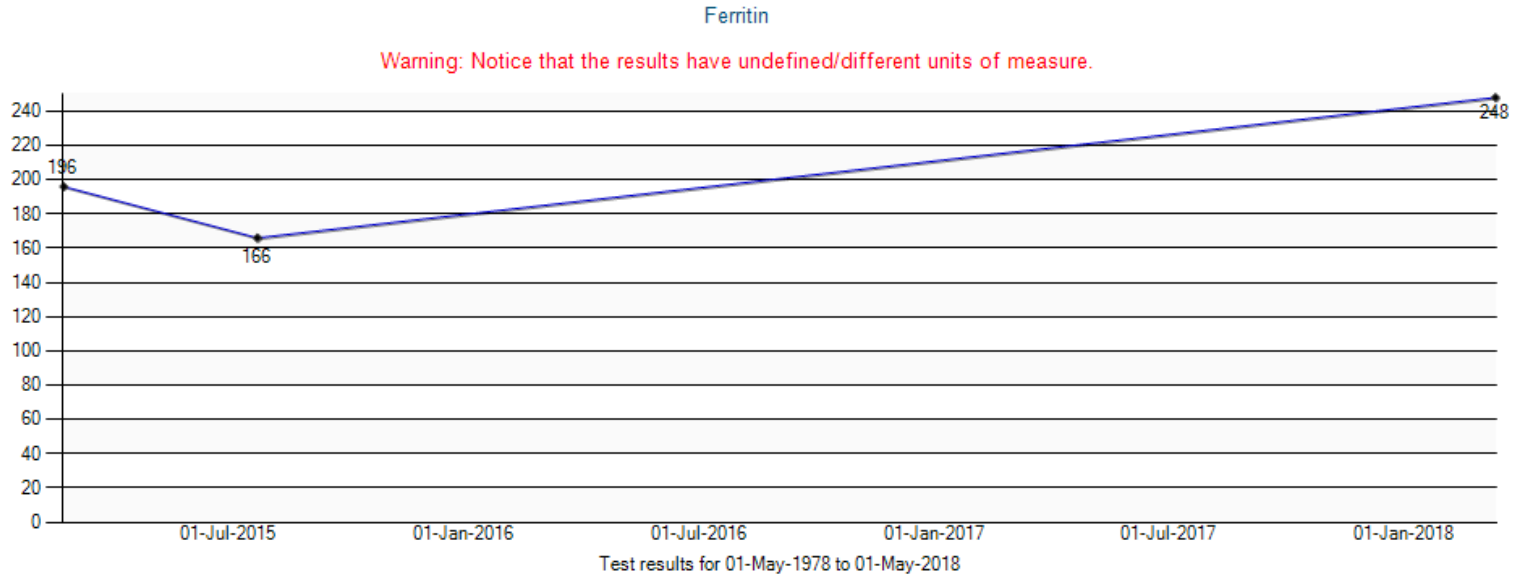


ANEMIA



* Alteration in MCV is generally modest, and MCV is often within normal range
** Uncommon to cause more than mild anemia; test according to clinical context

Case 1: more sleuthing in eChart



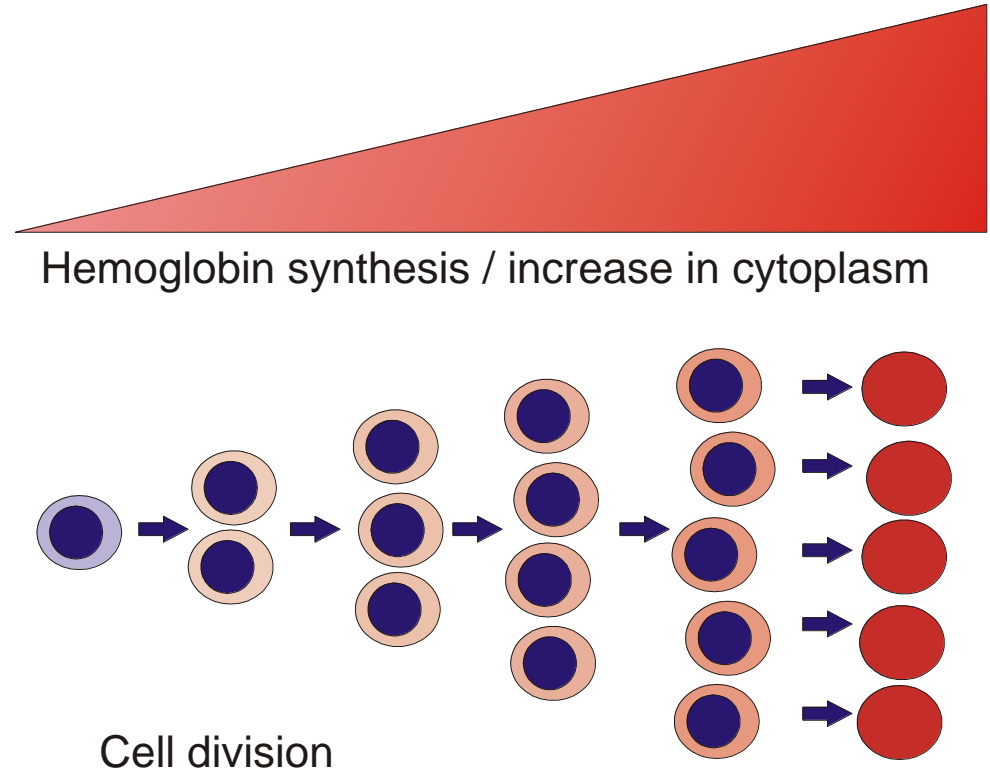
Case 1:

- What sources should we interrogate next?
- Would it help to know that her name is Mary Mwangi?

Deciphering the MCV

The 'balloon model'
of red cell
development

*All microcytic
anemias reflect
impairment of Hb
synthesis*



Case 1: Microcytosis – the culprit is...

- Circumstantial evidence points to diagnosis of alpha thalassemia trait (common in Africa)
- No further testing needed
- But what about the lymphocyte count?

Case 1: Exposing fake lymphocytosis

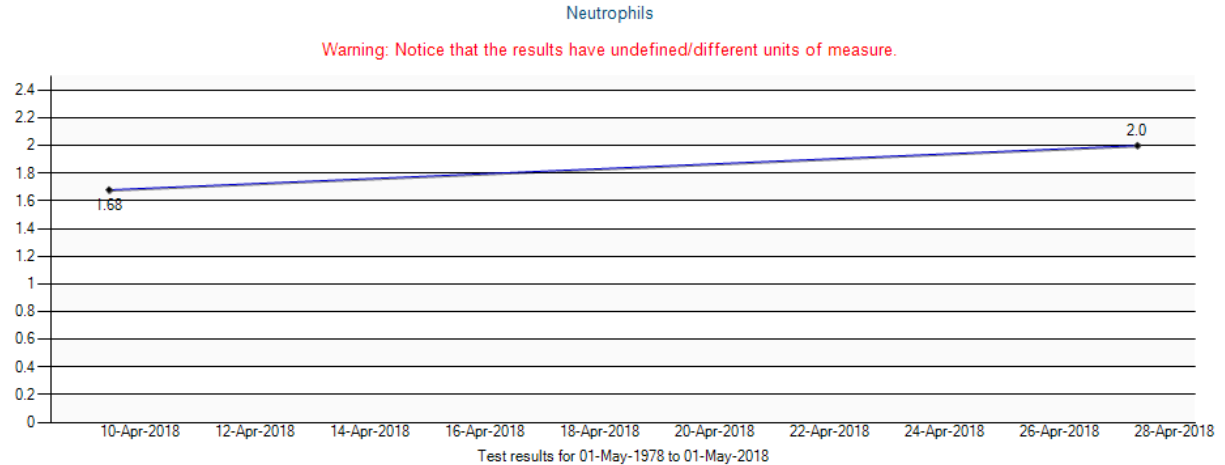
- WBC $4.1 \times 10^9/L$ (N = 4.5 – 11)
- Neut 33.5%
- Lym 59.1%
- Mono 6.4%
- Eos 0.8%
- Baso 0.2%

Case 1: Exposing fake lymphocytosis

- WBC $4.1 \times 10^9/L$ (N = 4.5 – 11)
- Neut 33.5% = $1.37 \times 10^9/L$ (N = 1.8 – 5.4)
- Lym 59.1% = $2.42 \times 10^9/L$ (N = 1.3 – 3.2)
- Mono 6.4% = $0.26 \times 10^9/L$ (N = 0.3 – 0.8)
- Eos 0.8% = $0.03 \times 10^9/L$ (N = 0.0 – 0.4)
- Baso 0.2% = $0.01 \times 10^9/L$ (N = 0.0 – 0.1)

Case 1: is there a second guilty party?

- ‘Benign ethnic neutropenia’
- Reference range for neutrophil count is lower in Africans



Learning point

- There is no use for percentage differential counts. It is the absolute value that matters!

Case 2: A dastardly double deal

- 36F from Nigeria referred for 'anemia NYD'
- Hx of latent TB
- WBC 4.9 x 10⁹/L
- RBC 5.3 x 10¹²/L
- Hb 105 g/L
- MCV 65 fL
- MCHC 304 g/L
- RDW 19.4
- What investigations should we do next?

Case 2

- 36F from Nigeria referred for 'anemia NYD'
- Hx of latent TB
 - WBC $4.9 \times 10^9/L$
 - RBC $5.3 \times 10^{12}/L$
 - Hb 105 g/L
 - MCV 65 fL
 - MCHC 304 g/L
 - RDW 19.4
- What investigations should we do next?
 - Serum iron
 - TIBC
 - Ferritin
 - B12

Case 2

- 36F from Nigeria referred for 'anemia NYD'
- Hx of latent TB
 - WBC $4.9 \times 10^9/L$
 - RBC $5.3 \times 10^{12}/L$
 - Hb 105 g/L
 - MCV 65 fL
 - MCHC 304 g/L
 - RDW 19.4
- What investigations should we do next?
 - Serum iron 8
 - TIBC 73
 - Ferritin 11
 - B12 772

Case 2:


- “Watson, I smell a rat. Something doesn’t fit”

What seems out of place?

- 36F from Nigeria referred for 'anemia NYD'
- Hx of latent TB
 - WBC $4.9 \times 10^9/L$
 - RBC $5.3 \times 10^{12}/L$
 - Hb 105 g/L
 - MCV 65 fL
 - MCHC 304 g/L
 - RDW 19.4
- What investigations should we do next?
 - Serum iron 8
 - TIBC 73
 - Ferritin 11
 - B12 772

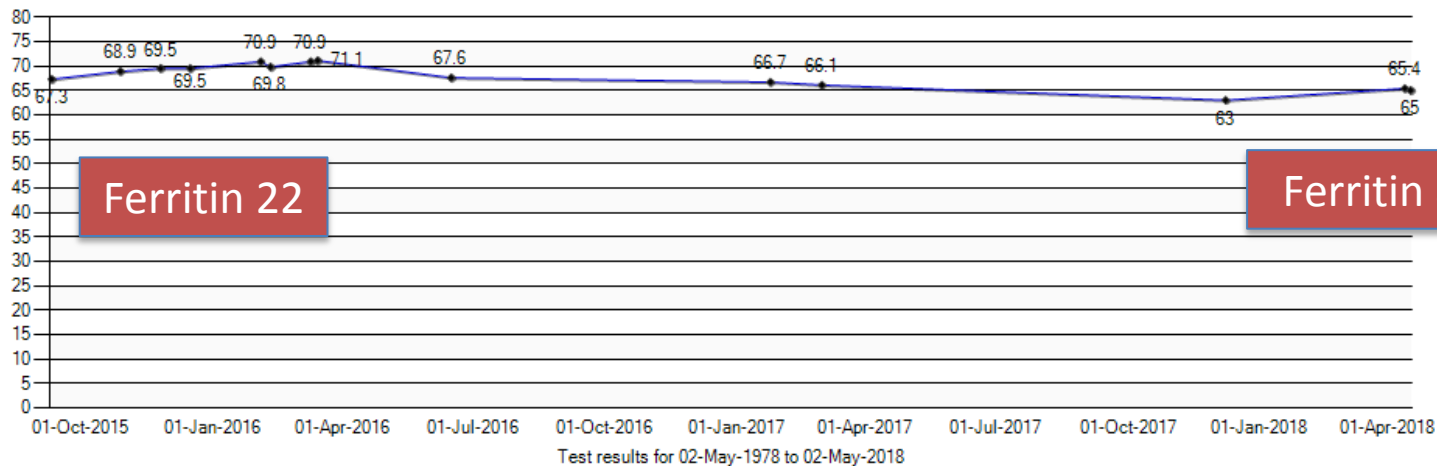
Hemoglobin

Warning: Notice that the results have undefined/different units of measure.



MCV

Warning: Notice that the results have undefined/different units of measure.



Case 3: The Masked Marauder

- 38F from Sioux Lookout referred for pancytopenia
- PHx as provided:
 - G9P10
 - well-documented iron-deficiency in the past
 - IVDU
 - Hyperthyroid

Case 3

- January 2018
 - WBC 3.2, ANC 1.0
 - Hb 64, MCV 75
 - RDW 23.1 (N = 11-14.5)
 - Platelets 98
 - Ferritin 8, Tsat 4%
 - Creatinine, LFTs N

Case 3

- January 2018
 - WBC 3.2, ANC 1.0
 - Hb 64, MCV 75
 - RDW 23.1 (N = 11-14.5)
 - Platelets 98
 - Ferritin 8, Tsat 4%
 - Creatinine, LFTs N
- March 2018
 - WBC 2.2, ANC 0.7
 - Hb 60, MCV 86
 - RDW 28.6
 - Platelets 90
 - Ferritin 22
 - LDH 342 (↑)

Case 3

What should we do next, Watson?

- A. Peripheral blood film
- B. Bone marrow aspirate
- C. Serum B₁₂
- D. Serum protein electrophoresis

Case 3

- Blood film:
 - “The red cells show rouleaux formation and some red cell clumping. Occasional elliptocytes are present, rare spherocytes are present. Rare target cells are seen. Polychromasia is not overly prominent. There is a neutropenia without any dysplastic forms. The rare atypical/reactive appearing lymphocyte is present. The platelets are decreased.
- SPEP:
 - “an ill-defined band in the mid-gamma globulin region is detected”
- Serum B12: “< **92pmol/L**”

Case 4: The man with the scar

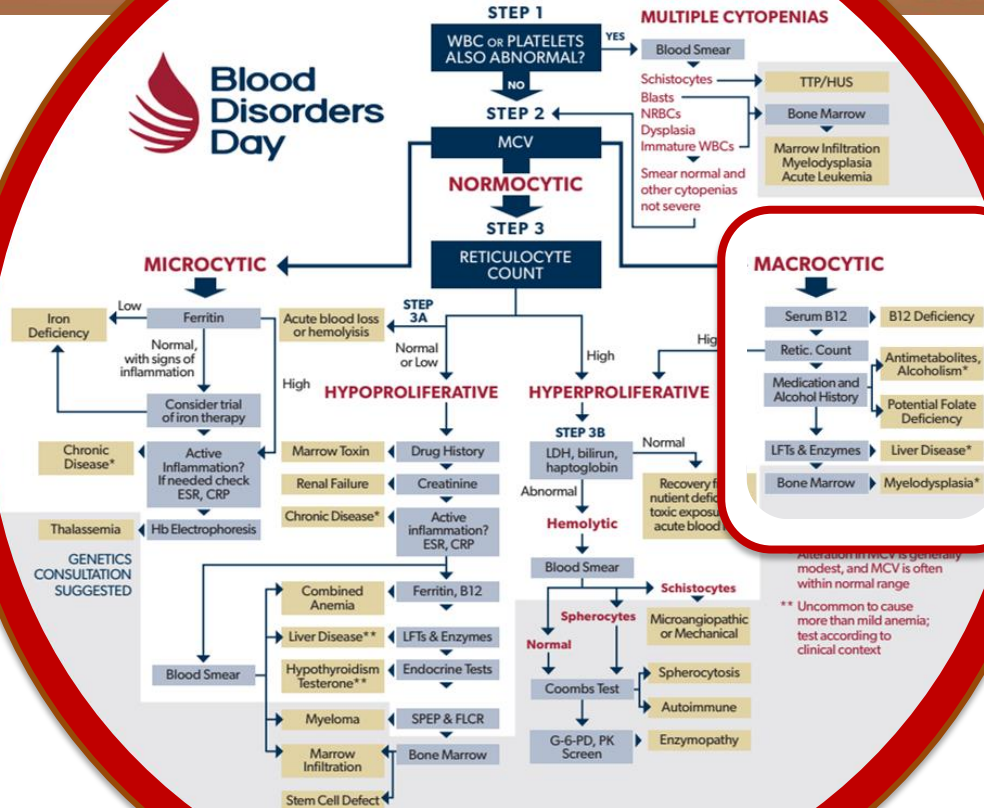
- 63M
- c/o generalized weakness
- PHx diabetes, arthritis
- WBC 2.7
- ANC 1.7
- Hb 130
- MCV 109
- Platelets 37

Case 4

That man sounds sick! Dr. Watson, what shall we do for him?

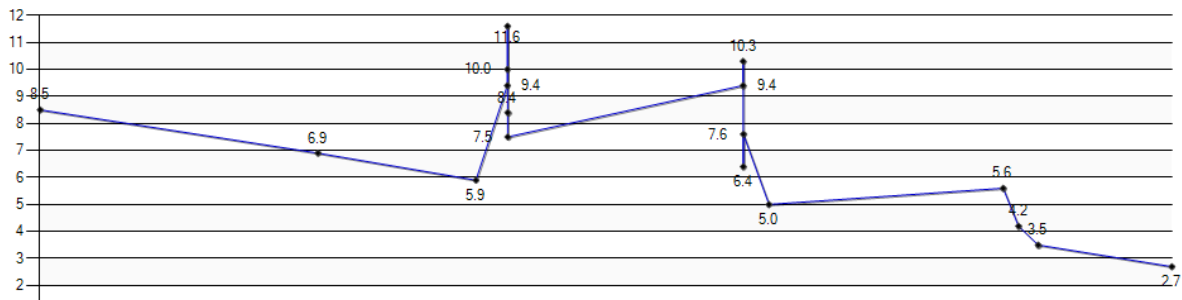
- A. Peripheral blood film
- B. Bone marrow aspirate
- C. Serum B12
- D. Liver enzymes
- E. Reticulocyte count

ANEMIA



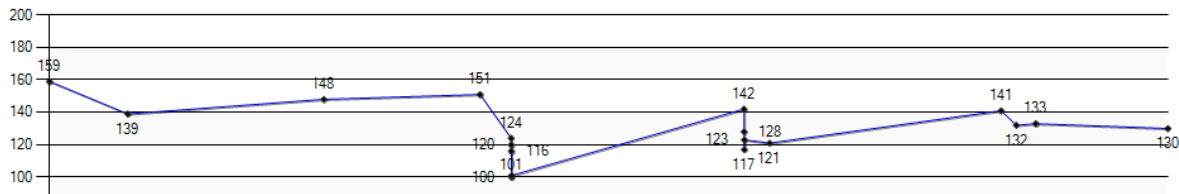
Alteration in MCV is generally modest, and MCV is often within normal range
** Uncommon to cause more than mild anemia; test according to clinical context

Warning: Notice that the results have undefined/different units of measure.



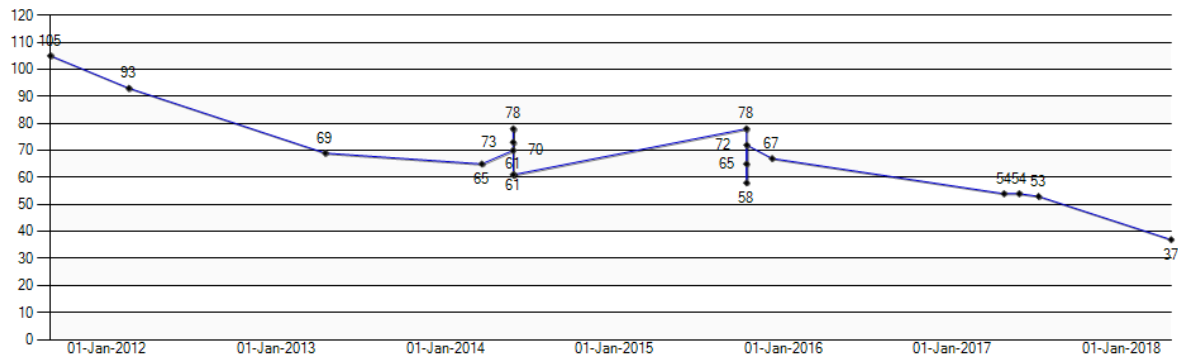
Hemoglobin

Warning: Notice that the results have undefined/different units of measure.



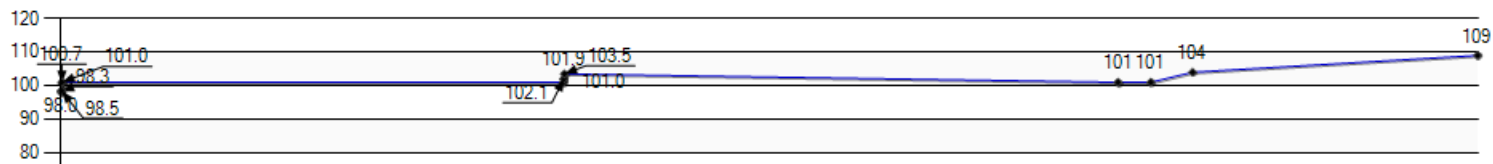
Platelets

Warning: Notice that the results have undefined/different units of measure.



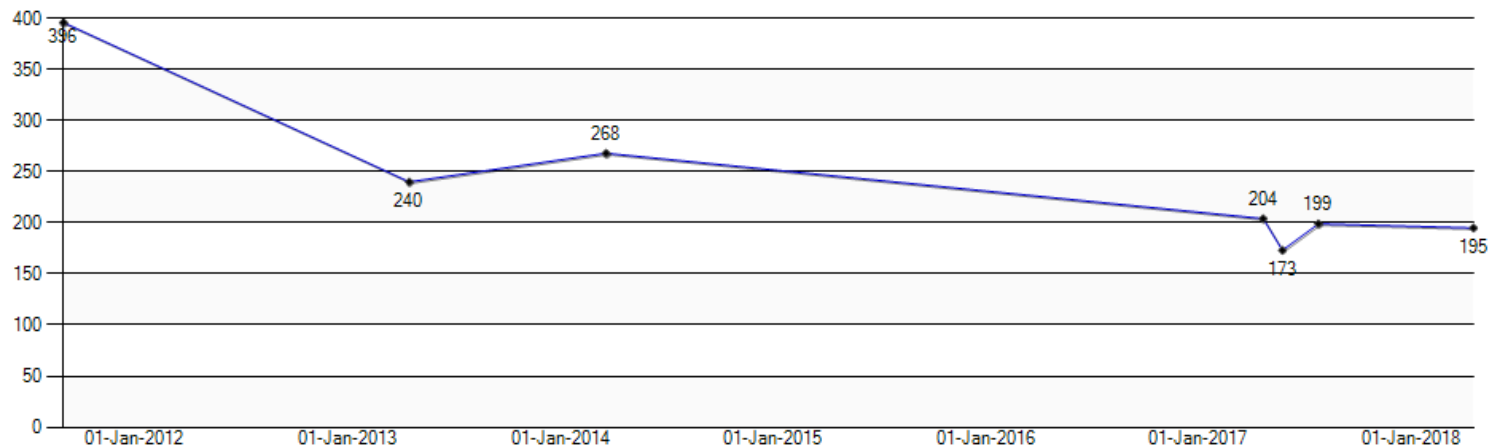
MCV

Warning: Notice that the results have undefined/different units of measure.



Vitamin B12

Warning: Notice that the results have undefined/different units of measure.



Case 4 – more labs

- AST 30, ALT 25
- Alk phos 108, GGT 138 (↑)
- T.bili 26 (↑), direct 10 (↑)
- INR 1.6 (in eChart)
- B₁₂ 195
- Fasting glucose 25

Watson:

“I always start by examining the patient, sir”

Case 4: The man with the scar

- U/S abdomen:
 - “The liver measures 18cm demonstrates a coarsened echogenicity/echotexture. The liver contour is irregular. This is unaltered and again in keeping with cirrhosis. No focal hepatic lesion is identified. The portal vein is patent and demonstrates normal direction of flow.
 - “The spleen is enlarged measuring up to 16.4cm with a volume of 512ml.”

Case 5: The next man


- 76M with postural lightheadedness and dyspnea with mild exertion
- Cut back on alcohol recently since cirrhosis identified
- PHx diabetes, smoking, hypertension

Case 5

- WBC 2.2, ANC 0.46
- Hb 85, MCV 109.8
- Platelets 28
- Reticulocytes $33 \times 10^9/L$
- No NRBCs or blasts
- Ferritin 166
- B₁₂ 945
- INR 1.0
- Creatinine 75

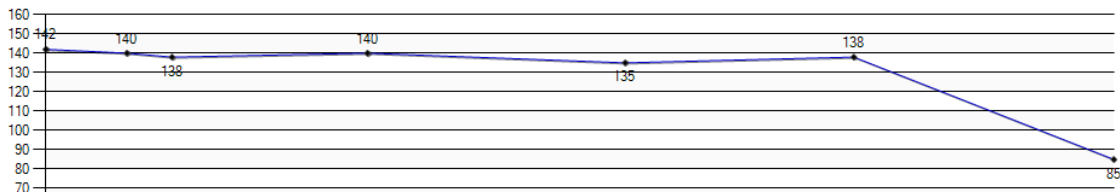
Leukocytes

Warning: Notice that the results have undefined/different units of measure.



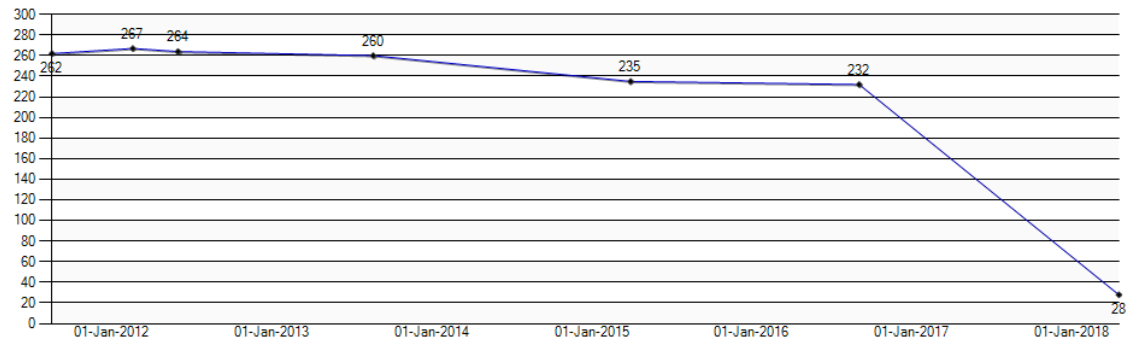
Hemoglobin

Warning: Notice that the results have undefined/different units of measure.



Platelets

Warning: Notice that the results have undefined/different units of measure.



Case 5

Who is the leading suspect?

- A. Cirrhosis with portal hypertension
- B. Myelodysplastic syndrome
- C. Aplastic anemia
- D. Marrow infiltration by tumour
- E. Acute leukemia

Case 5

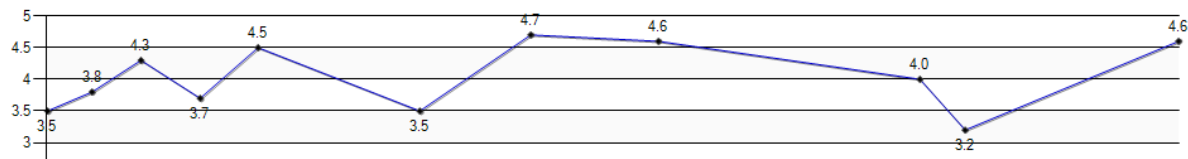
- U/S abdomen
 - “The liver demonstrates normal size. The liver contour is mildly lobulated. The porta is patent and demonstrates hepatopetal flow. No focal or diffuse lesions are seen. The spleen is normal. There is no ascites.”

Case 6: The little old lady in no distress

- 88F referred for low platelets
 - Platelets 93 on latest count provided ... from June 2017!
 - Hb 126, MCV 86, WBC 3.2, ANC 1.2
 - Liver enzymes, bilirubin, albumin all normal
 - U/S: Normal liver and spleen

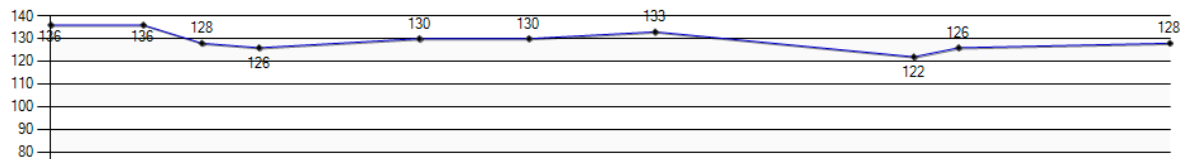
Leukocytes

Warning: Notice that the results have undefined/different units of measure.



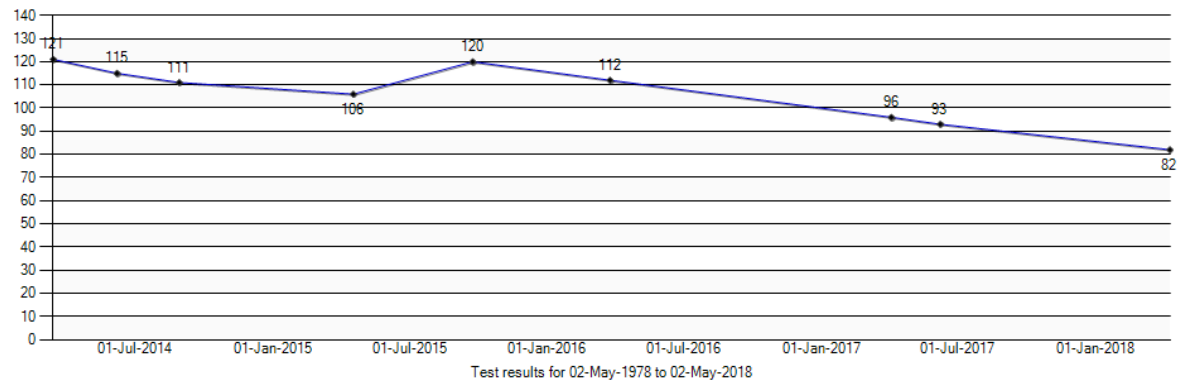
Hemoglobin

Warning: Notice that the results have undefined/different units of measure.



Platelets

Warning: Notice that the results have undefined/different units of measure.



Case 6

What is the best deduction here?

- A. Normal hemoglobin rules out myelodysplastic syndrome
- B. Minimal fluctuation in platelet count makes ITP unlikely
- C. This must be hypersplenism; are you sure it was her U/S you saw?
- D. She should see a hematologist, but her life expectancy is likely to be shorter than Dr. Houston's waiting list

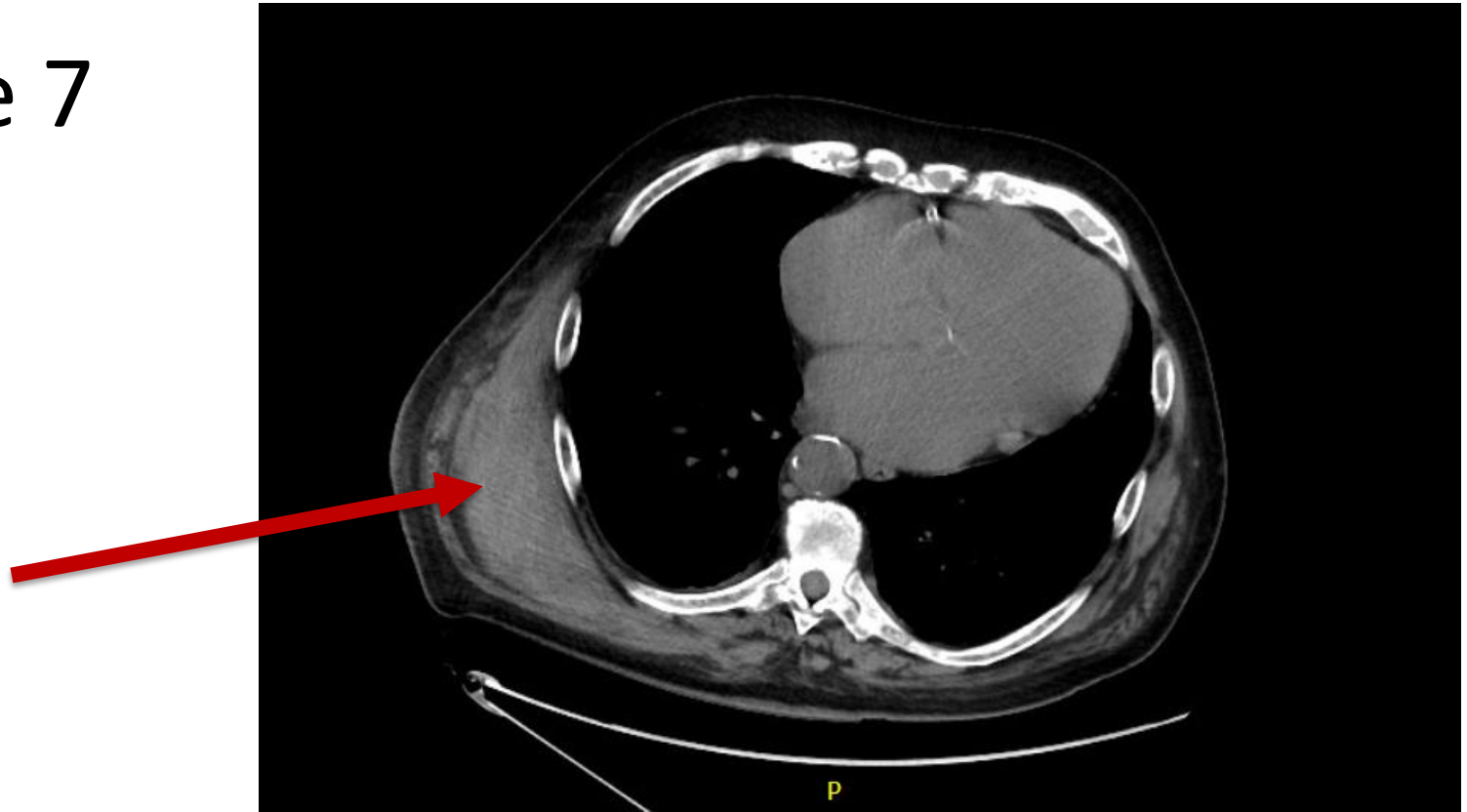
Learning point

- One of my rules of thumb is that chronic bone marrow failure disorders (e.g. myelodysplasia, megaloblastic anemia, myeloma) affect Hb more than other cell lines
- But that's a rule of thumb, not a law of nature!

Case 7: Double jeopardy

- 82M from Steinbach
- On warfarin for atrial fibrillation
- Suffers a fall and develops a large chest-wall hematoma
 - Hb falls from 143 to 95
- Referred because of high platelet count

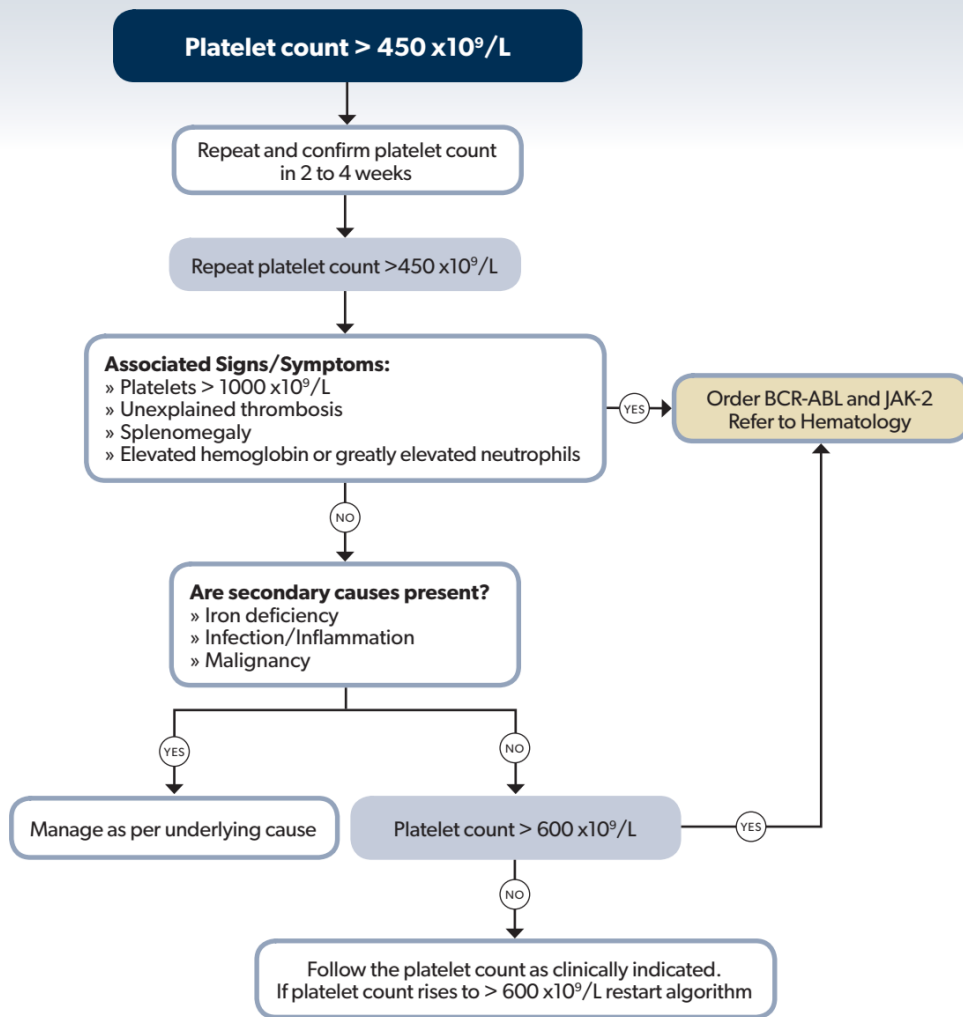
Case 7



Case 7

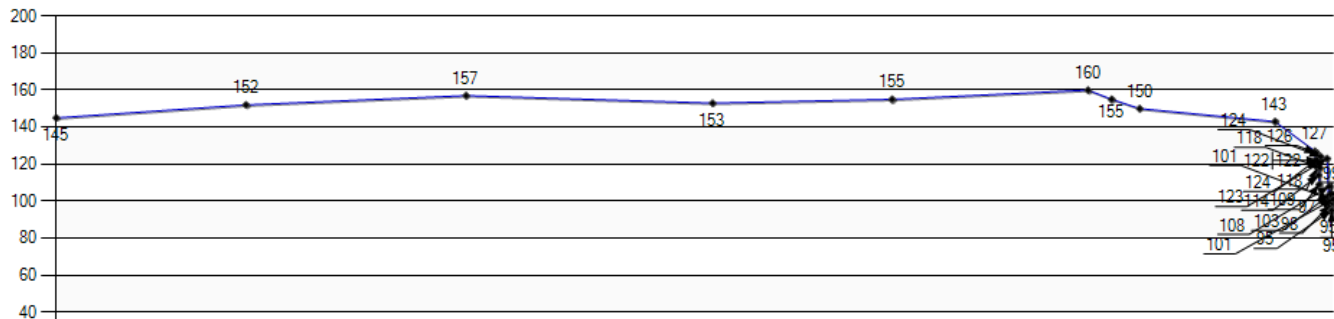
Which is most likely to be the abnormal finding here, Watson?

- A. CRP elevated
- B. Jak2 V617F present
- C. Low ferritin



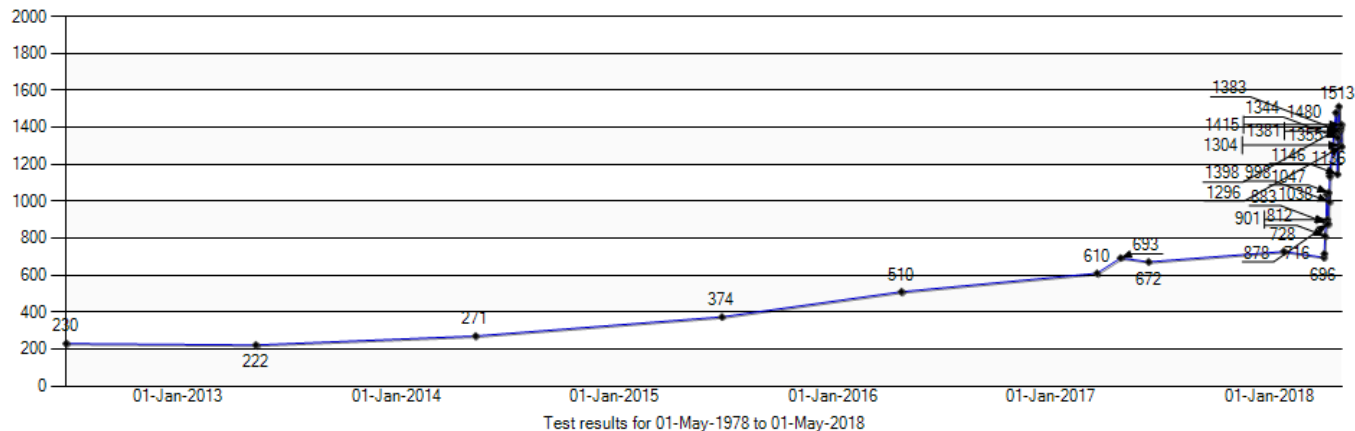
Hemoglobin

Warning: Notice that the results have undefined/different units of measure.



Platelets

Warning: Notice that the results have undefined/different units of measure.



Case 8: The florid felon

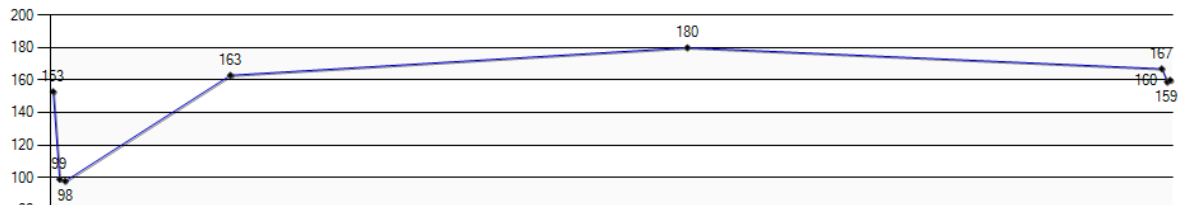
- 58F from Vita
 - Referred because of elevated Hb
 - Symptomatic with vertigo
- PHx fractured femur (still uses walker), lipids, anxiety, depression, hypertension (on perindopril)
- Smoker

Case 8

- O₂ sat 97%
- Shaky hands, nodding head
- BP 125/78

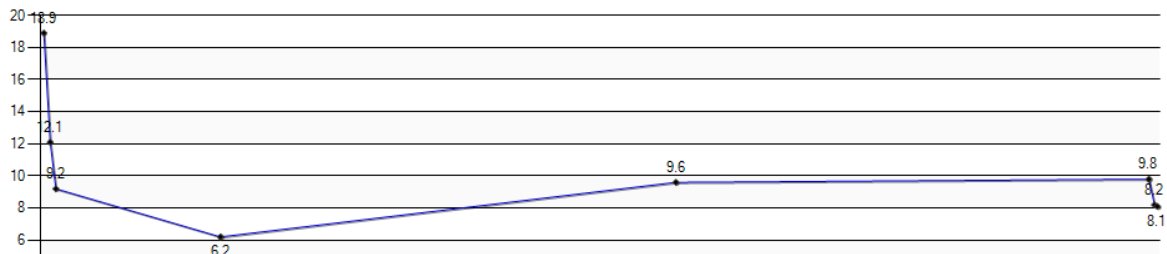
Hemoglobin

Warning: Notice that the results have undefined/different units of measure.



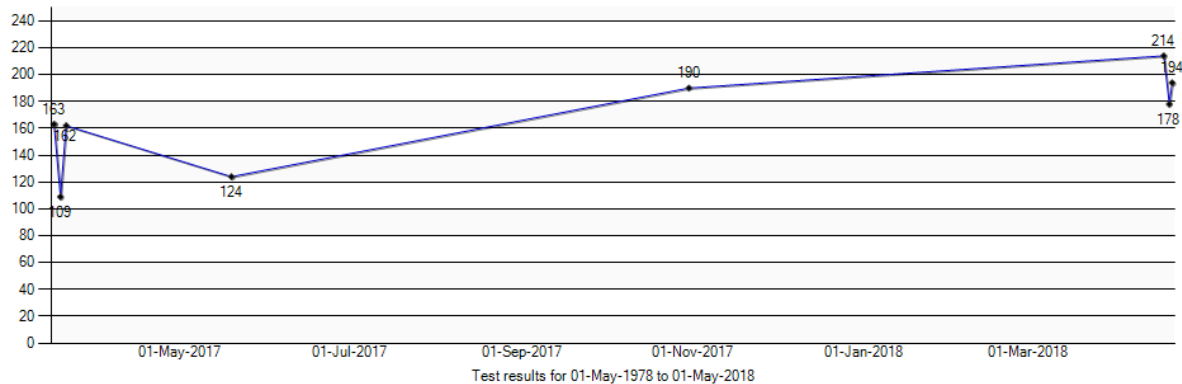
Leukocytes

Warning: Notice that the results have undefined/different units of measure.

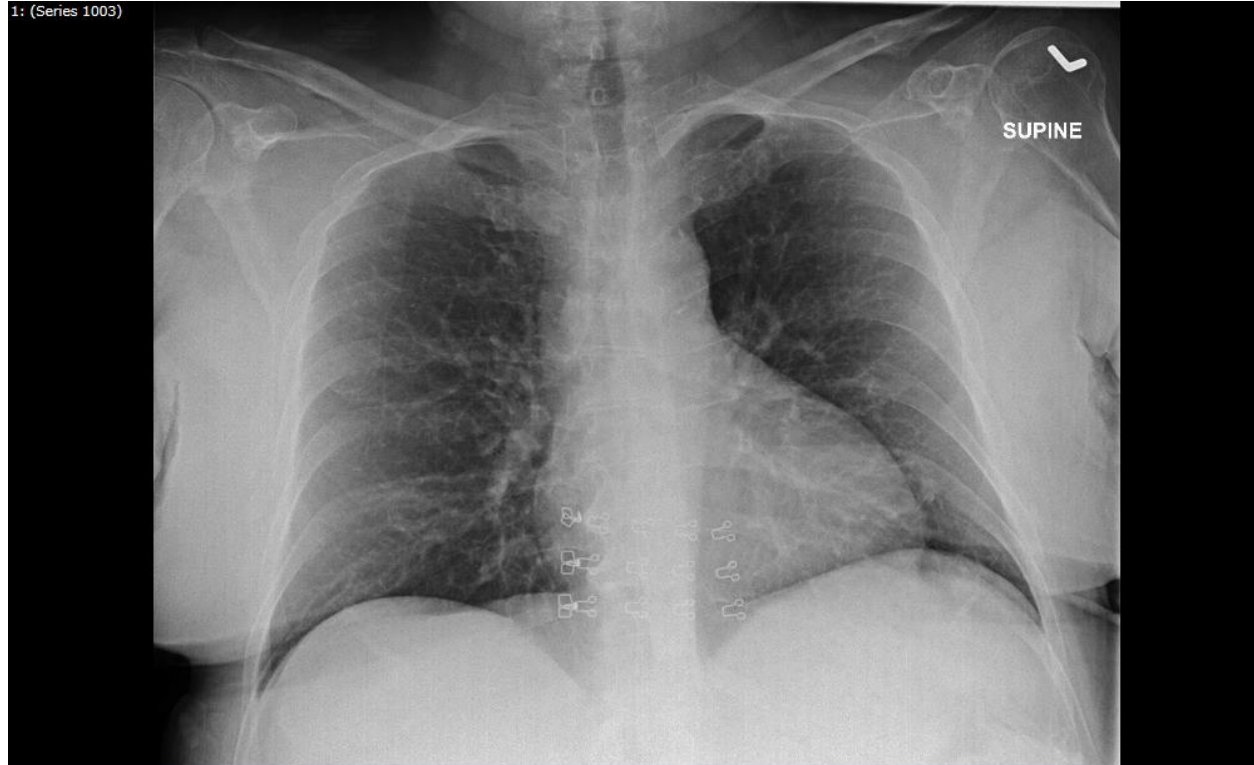


Platelets

Warning: Notice that the results have undefined/different units of measure.



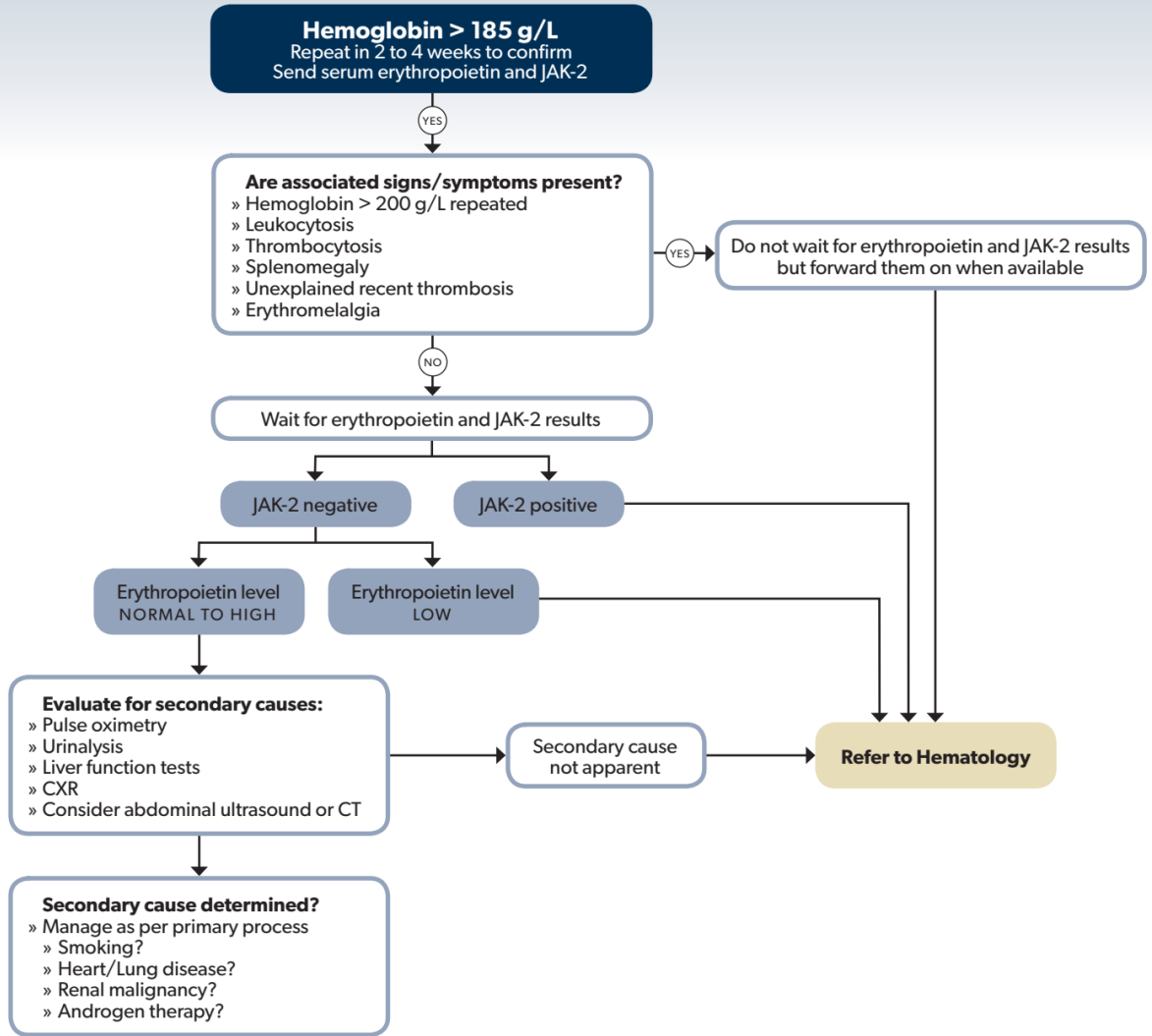
Case 8



Case 8

What tests would be appropriate in this patient (not necessarily all at once)?

- A. Jak2 V617F
- B. BCR-ABL
- C. Serum erythropoietin
- D. Sleep study
- E. Carbon monoxide level



Case 9: The Missing Soldiers

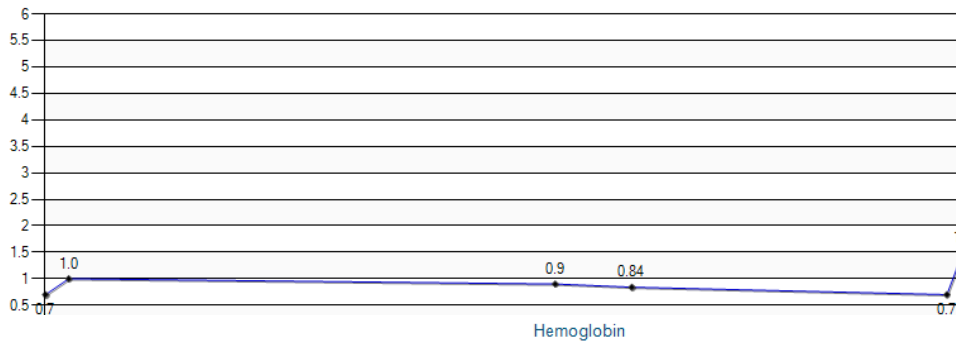
- 58 y.o. woman referred because of longstanding neutropenia
 - Investigated in 2002; bone marrow said to be normal
- Well for many years
- Admitted to ICU in December 2017 with pneumonia and respiratory failure. Also determined to have mitral valve disease (now repaired) and heart failure
- WBC 2.8, ANC 1.2, Hb 129, MCV 88, platelets 242

Case 9

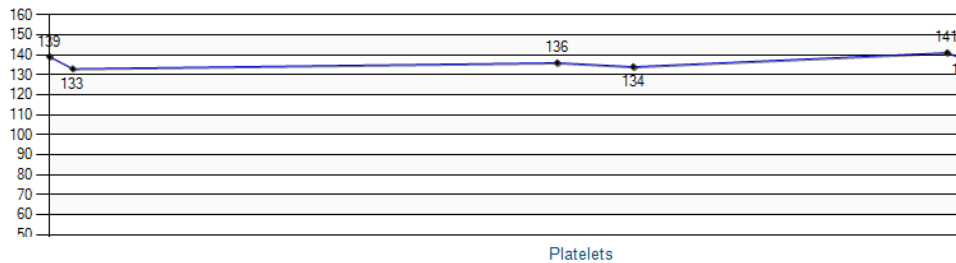
Should she have been treated over the years to prevent this catastrophe, and if so, how?

- A. Yes, with methotrexate or cyclosporine
- B. Yes, with G-CSF
- C. Yes, with bone marrow transplant
- D. No, her risk was low

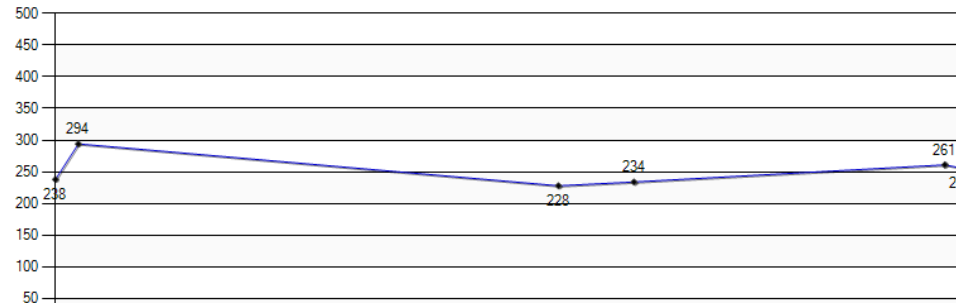
Warning: Notice that the results have undefined/different units of measure.



Warning: Notice that the results have undefined/different units of measure.



Warning: Notice that the results have undefined/different units of measure.



Case 10: The Overstuffed Corpuscles

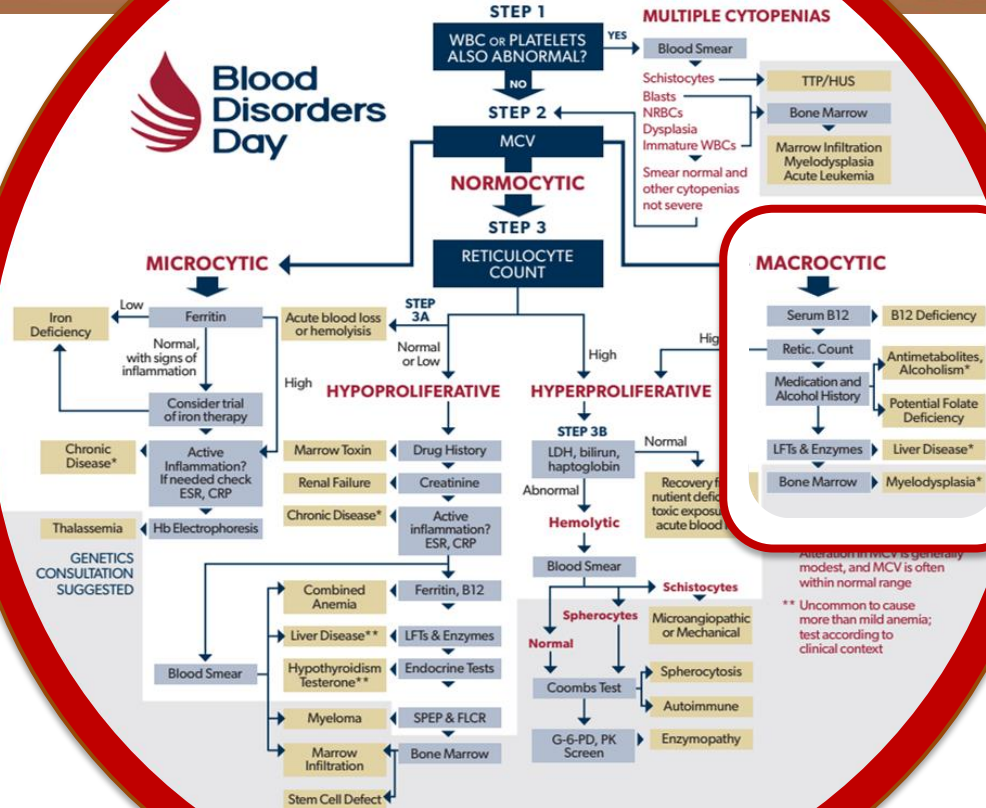
- 68F with history of rheumatoid arthritis
 - Well controlled on Methotrexate and sulfasalazine
- PHx of hypertension (on Dyazide) and hypothyroidism (on thyroxine)
- WBC 4.6, ANC 1.9, Hb 140, MCV 105, platelets 202

Case 10

What investigation will be most helpful to nab the offender responsible for overinflating her RBCs?

- A. Retic count
- B. B₁₂ level
- C. Folate level
- D. Liver function tests
- E. SPEP
- F. Bone marrow aspirate
- G. Review old lab values

ANEMIA



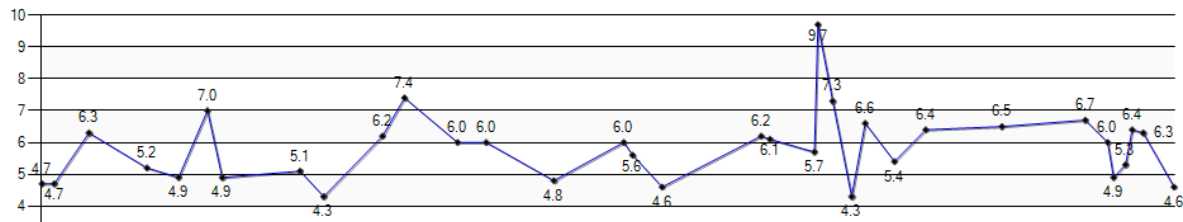
Alteration in MCV is generally modest, and MCV is often within normal range
** Uncommon to cause more than mild anemia; test according to clinical context

Case 10

- Retic count $96 \times 10^9/L$
- B_{12} 1034
- Homocysteine 9.5 $\mu\text{mol/L}$ (N = 4.5 – 13)
- Liver enzymes normal
- SPEP: No M protein, IgG slightly reduced

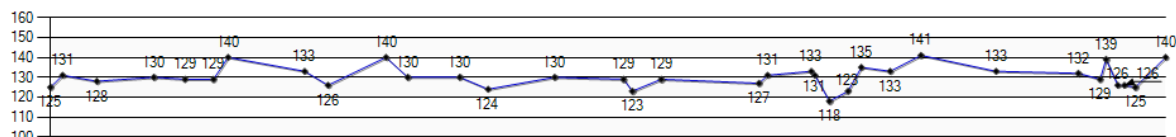
Leukocytes

Warning: Notice that the results have undefined/different units of measure.



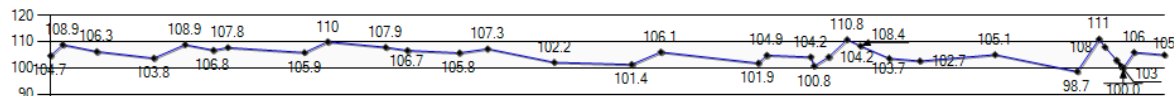
Hemoglobin

Warning: Notice that the results have undefined/different units of measure.



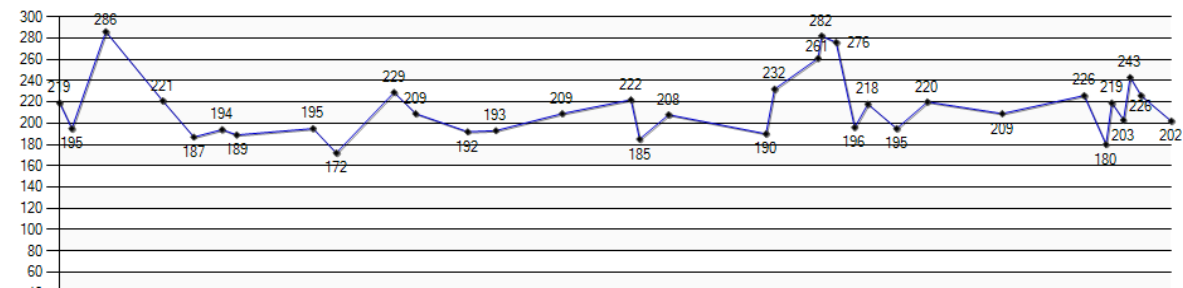
MCV

Warning: Notice that the results have undefined/different units of measure.



Platelets

Warning: Notice that the results have undefined/different units of measure.



Case 11: Sherlock's nemesis

- 42M from Wanipigow. Generally well.
- Hb 177, MCV 77.1, RBC 7.02, MCHC 327
- Iron 49.3, TIBC 69.2, Tsat 71%, ferritin 272
- Other labs: elevated liver enzymes, cholesterol, triglycerides
- All values similar on repeat testing 2 months later

Case 11

Microcytosis in this gentleman is most likely attributable to

- A. Iron deficiency
- B. Inflammation ('anemia of chronic disease')
- C. Thalassemia trait
- D. Lead poisoning
- E. Erythropoietic protoporphyria
- F. Congenital sideroblastic anemia

Take home

- The best diagnosis is the one that explains the largest number of salient abnormalities
- Review of previous bloodwork is often the most useful ‘test’
- No clue is too small to help inform a diagnosis, but some clues are more important than others

Thank you

houston@cc.umanitoba.ca

